



© J ORTHOP TRAUMA SURG REL RES
18(6) 2023
Method Article

Double fixation of flexor hallucis longus tendon transfer technique in chronic tendoachilles tear

BUSHU HARNA (1), MANINDER S SINGH (2)

(1) MS Orthopaedics, Indus Hospital, Panjab, India

(2) MS Orthopaedics, Indian Spinal Injuries Centre, Delhi, India

Address for correspondence:

Bushu Harna, MS Orthopaedics, Indus Hospital, Panjab, India

bushu.edu@gmail.com

Statistics

Figures	04
Tables	00
References	05

Received: 19.05.2023; Manuscript

No. jotsrr-23-99375;

Editor assigned: 22.05.2023,

PreQC No. jotsrr-23-99375 (PQ);

Reviewed: 27.05.2022, QC No.

jotsrr-23-99375 (Q);

Revised: 29.05.2023,

Manuscript No. jotsrr-23-99375

(R);

Published: 02.06.2023,

DOI. 10.37532/1897-

2276.2023.18(6).88

Abstract

The chronic Tendoachilles (TA) tear is a complex orthopaedics problem. The challenges involve the tendon gap, degenerative changes at the tendon ends, wound complications, and difficulty in rehabilitation. Flexor Hallucis Transfer (FHL) is the standard procedure in such conditions. There are various benefits and techniques of FHL transfer in chronic TA tear. The FHL fixation can be performed with tenodesis screw, bone anchors, and other innovative methods like buttons fixed below the heel. This method of FHL fixation utilized the tenodesis screw and endobutton. This not only provided better biomechanical fixation but also gave a to modulate the FHL transfer tensioning.

Keywords: Chronic tear; large tear; tendon transfer; plantarflexion; strength

INTRODUCTION

There are various techniques to manage chronic Tendoachilles tendon (TA) tears. The management depends upon the tear gap and margin status of the TA tendon. Generally, chronic tears have a large tear gap (>4cm) with poor margins of the tendon [1]. The tendon can be injured and torn from the insertion site or it can be a mid-substance tear of the tendon. The insertional tear can be managed with reattachment of the tendon if feasible. In cases where the reattachment is not amenable, fascia plasty, allograft tendon, or tendon transfer can be performed. Flexor Hallucis Longus (FHL) tendon transfer in such cases can lead to alleviation of pain and disability [2]. The FHL tendon is lying in close proximity to the TA tendon and is in-phase with the TA tendon during the gait cycle. Although there are other tendons like flexor digitorum longus or peroneal tendon feasible for such transfer. The muscle strength and volume of the FHL tendon are more appropriate for tendon transfer in chronic TA tears [3]. The FHL tendon transfer in such patients leads to almost equal maximal strength of plantarflexion with good function but with reduced endurance [4]. The reduced plantarflexion strength of the great toe might be compensated by other tendons/muscles and pose no functional disability to the patient [4]. There are various techniques of FHL tendon transfer in chronic TA tears involving re-routing the FHL tendon through or side-ways of the TA tendon [5]. There are various fixation techniques and devices utilized in such transfers involving screws, endobutton, and anchors.

Here we present a simple and easy technique of double fixation of FHL transfer in chronic TA tendon tears leading to early rehabilitation and functional outcome.

SURGICAL TECHNIQUE

FHL tendon transfer in chronic TA tear not amenable to repair is a feasible option. Preoperatively, MRI is performed to evaluate the TA tear gap and margin status as well as to delineate the FHL tendon. Although ultrasonography can be utilized to assess the tear gap and margins. Clinical examination revealed grade 5 muscle strength of the FHL tendon. There was a palpable gap at the insertion of the TA tendon.

The patient was positioned prone with 10-150 of knee flexion and a mid-thigh tourniquet was applied. The incision was given over the TA tendon extending 7 cm-8 cm proximally from the insertion site just proximal to the proximal TA stump. The dense fibrous tissue at the TA tear site was excised. The proximal TA tendon stump was identified and 1 cm stump of Achilles was debrided. The TA tear gap was 8 cm. There was no distal stump of the TA tendon at the insertion site. The superior part of the posterior calcaneum tuberosity (Haglund deformity) was resected in a beveled manner from posterior-inferior to the anterior superior direction with help of the saw blade (Fig. 1). The FHL tendon was identified as passing lateral to medial direction deep to the Achilles tendon and stretching led to great toe flexion movement. The FHL tendon transfer insertion site was marked 1 cm-1.5 cm anterior to the Achilles tendon insertion on the superior beveled surface of the calcaneum. The FHL tendon was traced as distally possible from the same incision. The

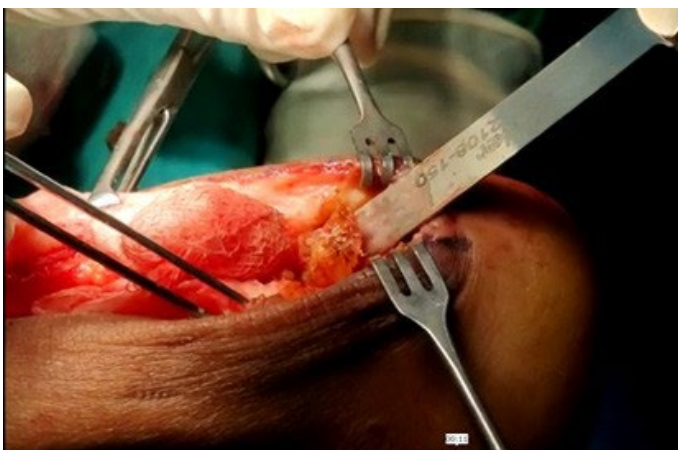

Fig. 1. Beveling of the calcaneal tuberosity with the saw blade

distal end of the FHL tendon was cut and the tendon was harvested. A traction stitch was placed at the distal FHL end and sizing of the tendon (5 mm) was done (Fig. 2). Proximally the FHL tendon was dissected and freed from all adhesions for better excursion. A 4 mm tunnel was drilled through the calcaneum from the proposed FHL insertion site on the beveled calcaneum surface. The direction of the tunnel should be aimed 1 cm anterior to the plantar surface of calcaneal tuberosity in the midline of the calcaneum. The length of the tendon to be inserted in the tunnel was marked according to the tunnel length and tensioning of the tendon (Fig. 2). Whipstitch along with a 10 mm endobutton was placed at the distal end of FHL. The 25 mm of the tunnel was drilled with a 6 mm reamer for the tenodesis screw. The endobutton was then placed in the tunnel and flipped on the plantar surface of the calcaneum. The tendon was then inserted in the tunnel and tensioned appropriately with the ankle in the neutral position (Fig. 3). The FHL tendon transfer was completed with a 25 mm x 7 mm tenodesis screw in the tunnel (Fig. 4). Proximally the FHL tendon belly was sutured from side to side with the proximal stump of the TA tendon. The wound was closed in layers with paratenon of the Achilles tendon over the FHL tendon. The skin closure was performed with the ankle in the neutral position. The below knee slab was given for 10 days for better pain relief and wound healing.

COMPLICATIONS

The surgeon should be cautious regarding the neurovascular bundle, lying in close proximity. Blunt dissection is advisable to prevent

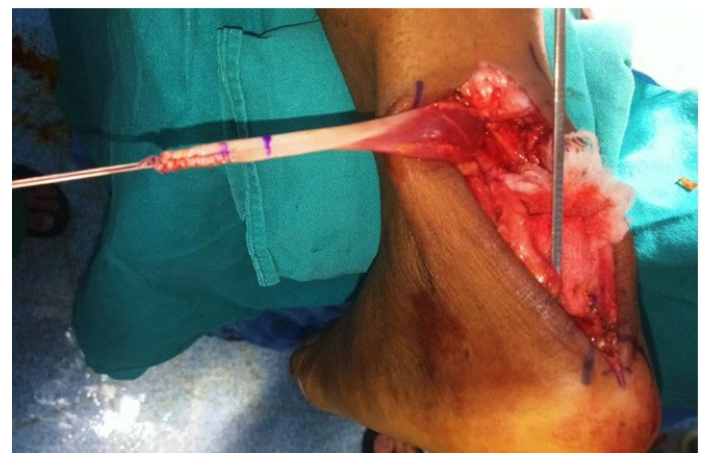

Fig. 2. Depicting the dissected FHL tendon with traction stitch

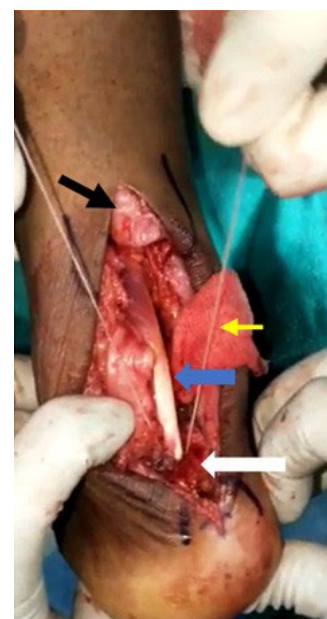


Fig. 3. Depicting the Distal stump of the TA tendon (black solid arrow), FHL tendon (blue solid arrow) inserted at the site on beveled calcaneal tuberosity (white solid arrow) with the help of endobutton (threads marked by yellow solid arrow).

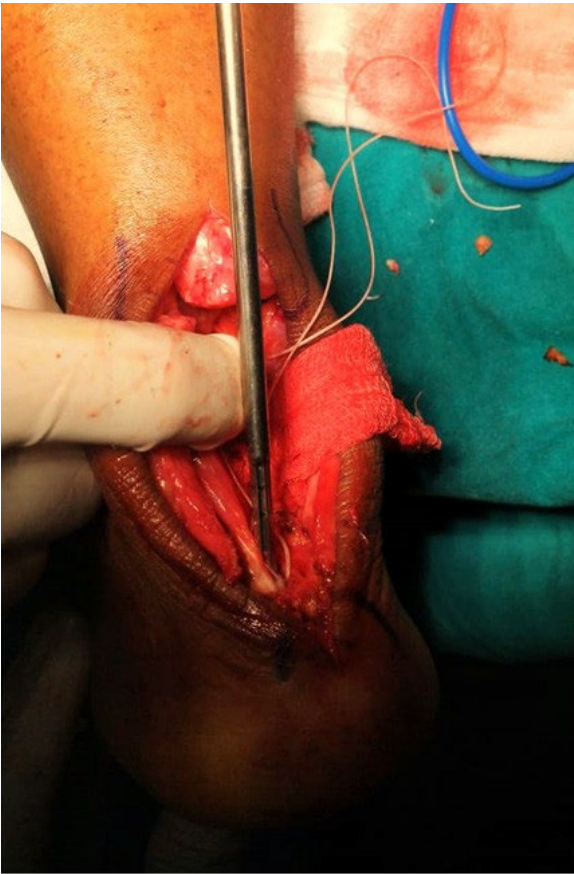

Fig. 4. FHL tendon fixed with tenodesis screw

injury to the neurovascular bundle. The FHL should be traced distally and dissected proximally for appropriate tendon length and tendon excursion. The FHL tendon can be harvested distally from the same incision, so no different incision is required. The calcaneum tunnel is oblique, in centre and 1 cm-1.5 cm anterior to ta tendon insertion. The length of the FHL tendon in the tunnel should be pre-measured so that the tensioning of the tendon can be done accordingly. The endobutton

should be placed anterior to the calcaneal tuberosity. The ankle position during the final tensioning of the tendon is neutral. Post-operatively the ankle should not be immobilized in plantarflexion, a neutral position is desirable.

DISCUSSION

FHL tendon is the most appropriate graft for chronic ta tear with large gaps. FHL tendon is located in close proximity to TA so a different incision is not required to harvest the tendon. The FHL tendon is in-phase with the TA tendon during the gait cycle. Thus, FHL tendon transfer leads to regain of the ankle plantarflexion during the static and dynamic phases. FHL tendon is preferred due to significantly greater muscle volume and strength than the flexor digitorum longus and peroneal tendons. The plantarflexion of the ankle requires a high degree of force, sustained by the FHL tendon so dual fixation with endobutton and tenodesis screw is desirable.

The advantages of this technique are less morbidity and fewer wound complications. Faster rehabilitation can be performed with near-to-full power of ankle plantarflexion regained over 4 weeks-6 weeks. No adverse functional effects on great toe plantarflexion. The patient was mobilized with help of a walker for 2 weeks post-surgery and later on with a stick. The patient was able to walk independently over 4 weeks-6 weeks post-surgery.

During the follow-up of 1 year, the patient had similar power of ankle plantarflexion as compared to the other side and walking normally. The patient was able to perform all the activities of daily living as well as occupational activities without any aid. There was no complaint of pain or wound complications.

CONCLUSION

This fixation method provided better biomechanical strength for the FHL transfer fixation. This led to early aggressive rehabilitation and better results. The wound complication is no different from any FHL transfer technique. This technique also helped to modulate the tension of the FHL tendon transferred. The tendon in the bone tunnel length could be modulated and fixed with endobutton further stabilised with tenodesis screw.

References:

1. Park YS, Sung KS. Surgical reconstruction of chronic Achilles tendon ruptures using various methods. *Orthopedics*. 2012;35(2):e213-8. .
2. Gabel S, Manoli A. Neglected rupture of the Achilles tendon. *Foot & ankle international*. 1994;15(9):512-7.
3. Jeng CL, Thawait GK, Kwon JY, et al. Relative strengths of the calf muscles based on MRI volume measurements. *Foot & Ankle International*. 2012;33(5):394-9.
4. Alhaug OK, Berdal G, Husebye EE, et al. Flexor hallucis longus tendon transfer for chronic Achilles tendon rupture. A retrospective study. *Foot and Ankle Surgery*. 2019 Oct 1;25(5):630-5.
5. Wegrzyn J, Luciani JF, Philippot R, et al. Chronic Achilles tendon rupture reconstruction using a modified flexor hallucis longus transfer. *International orthopaedics*. 2010;34:1187-92.