

See discussions, stats, and author profiles for this publication at: <https://www.researchgate.net/publication/374330490>

Diffuse alveolar hemorrhage in orthopaedic surgery: Think beyond embolism- A case report

Technical Report · September 2023

CITATIONS

0

READS

28

3 authors, including:



Bushu Harna

Maulana Azad Medical College

38 PUBLICATIONS 68 CITATIONS

SEE PROFILE



Lalit Gupta

Maulana Azad Medical College

141 PUBLICATIONS 170 CITATIONS

SEE PROFILE

Diffuse Alveolar Hemorrhage in Orthopaedic Surgery: Think Beyond Embolism - A Case Report

Ortopedik Cerrahide Diffüz Alveoler Kanama: Embolizmin Ötesini Düşünün - Olgu Sunumu

 Bushu Harna¹,  Shivali Arya²,  Lalit Gupta³

Abstract

Diffuse alveolar hemorrhage (DAH) is a dreaded and life-threatening complication. Although it is rarely reported in postoperative orthopaedic patients but few cases of fat embolism-associated DAH had been reported in the literature. We report a postoperative intramedullary femur patient with underlying undiagnosed vasculitis presenting as diffuse alveolar hemorrhage. A 56-year-old gentleman suffered a right femur fracture, managed with an interlocking nail. On postoperative day 4, the patient presented with hemoptysis, dyspnea, and a sudden fall in hematocrit suspecting diffuse alveolar hemorrhage (DAH). Pulmonary angiography and other investigations were not suggestive of pulmonary thromboembolism or fat embolism. Vasculitis was then suspected and cANCA (PR3) antibodies were positive. The patient was managed with corticosteroids, methotrexate, and oxygen supplementation. At 1 year follow-up, the femur fracture had united with no respiratory problem. As a conclusion, vasculitis, though a rare cause of DAH in post-operative orthopaedic surgery patients should be kept in mind.

Keywords: Diffuse alveolar hemorrhage, orthopaedic surgery, respiratory distress, vasculitis, bronchoalveolar lavage, respiratory distress.

Öz

Diffüz alveolar kanama (DAH) korkulan ve hayatı tehdit eden bir komplikasyondur. Postoperatif ortopedik hastalarda nadiren bildirilmesine rağmen, literatürde az sayıda yağ embolisi ile ilişkili DAH olgusu bildirilmiştir. Diffüz alveolar hemoraji ile prezente, tanı konmamış vaskülitli olan postoperatif intramedüller femur hastasını sunuyoruz. Elli altı yaşında erkek, sağ femur kırığı sonrası kilitleli bir çivi takılarak opere edildi. Postoperatif 4. günde hastada, hemoptizi, nefes darlığı ve diffüz alveoler kanamadan (DAH) kaynaklanan hematokritte ani bir düşüş saptandı. Pulmoner anjiyografi ve diğer incelemelerde pulmoner tromboemboli veya yağ embolisi görülmedi. Daha sonra vaskülitten şüphelenildi ve cANCA (PR3) antikorları pozitif bulundu. Hasta, kortikosteroid, metotreksat ve oksijen desteği ile tedavi edildi. Bir yıllık takipte femur kırığı solunum sorunu olmadan iyileşti. Sonuç olarak, vaskülit, ortopedik cerrahi sonrası hastalarda nadir görülen bir DAH nedeni olsa da akılda tutulmalıdır.

Anahtar Kelimeler: Diffüz alveoler kanama, Ortopedik cerrahi, solunum zorluğu, vaskülit, bronkoalveolar lavaj, solunum zorluğu.

¹Indus Hospital, Mohali, Panjab, India

²Government medical college and hospital, Chandigarh, India

³Maulana Azad Medical College, New Delhi, India

¹İndus Hastanesi, Mohali, Pencap, Hindistan

²Devlet tıp fakültesi ve hastanesi, Chandigarh, Hindistan

³Mevlana Azad Tıp Fakültesi, Yeni Delhi, Hindistan

Submitted (Başvuru tarihi): 09.05.2023 **Accepted (Kabul tarihi):** 16.06.2023

Correspondence (İletişim): Bushu Harna, Indus Hospital, Mohali, Panjab, India

e-mail: bushu.edu@gmail.com



Many postoperative orthopedic complications can lead to serious morbidity and mortality, and specific complications common to femoral intramedullary nailing include pulmonary embolism and fat embolism (1). Diffuse alveolar hemorrhage (DAH) is a life-threatening condition that can be associated with postoperative fat or pulmonary embolism (2,3), while a rarer cause can be an underlying undiagnosed immune disorder like vasculitis. Despite various radiological and laboratory investigations, the etiology of DAH has yet to be ascertained, and in such cases, immune disorders such as vasculitis should be considered. In this first-case presentation, we report on a patient with vasculitis (granulomatosis with polyangiitis) as the causative factor for the development of DAH post-intramedullary femoral nailing.

CASE

A 56-year-old male suffered an injury to his right thigh in a road traffic accident. Upon presentation in the emergency room the patient was conscious and oriented with stable vital parameters and no other visceral injuries. Radiographs revealed a fracture of the femur shaft with no other bone injuries. Laboratory investigations revealed hemoglobin (Hb): 14.2g/dL, platelet 3.2×10^5 /dL, total leukocyte count (TLC): $11300/\text{mm}^3$, urea: 34 mg/dL, serum creatinine: 0.9mg/dL, total bilirubin: 0.8mg/dL, alanine transaminase/aspartate transaminase (ALT/AST): 38/42 U/L, prothrombin time (PT): 14 seconds and international normalized ratio (INR): 1.1, while a chest radiograph and electrocardiography were both normal. The limb was splinted and fluid resuscitation was performed for the next 48 hours. The Hb was 13.6 g/dL with rest normal parameter the day before surgery. On the 3rd day following admission, the fracture was repaired with an interlocking femur nail while the patient was under spinal anesthesia with bupivacaine hydrochloride 0.5% w/v (heavy). The duration of surgery was around 1 hour and 10 minutes, during which no intraoperative complications were encountered, and the postoperative period was also uneventful. The patient was well hydrated with normal saline (0.9%) in the postoperative period with no requirement of supplemental oxygen for the next 48 hours. The patient was mobilized on post-op day 1 with the help of a walker. The day after surgery, the patient's Hb was 12.4g/dl and aspirin (acetylsalicylic acid) 75mg/day was started. The mobility of the patient continued on the following 2 days (until postoperative day 3).

In the evening of post-op day 4 the patient had an episode of hemoptysis and coughing, and streaks of bright red blood were noted in every cough thereafter. Over 15 minutes, the patient was dyspneic with fingertip oxygen saturation of 80–83% in room air. The patient was admitted to the ICU and given supplemental oxygen by reser-

voir mask at a rate of 8 L/min. The vital parameters of the patient were stable with a radial pulse rate of 132/min, and fingertip oxygen saturation (SpO_2) with supplemental oxygen after 15–20 mins was 92–95%. Fluid resuscitation was continued, and the patient was kept under observation. The frequency of hemoptysis episodes increased over the next 12 hours. The patient was hemodynamically stable, but his respiratory rate increased to 28–30/min. The labored breathing increased, and the patient was given BIPAP ventilation with an inspiratory positive airway pressure of 12 mm Hg, expiratory positive airway pressure of 6mm Hg and oxygen flow rate of 10L/min. A chest radiograph revealed diffuse alveolar infiltrates in bilateral lung fields (Figure 1a). Laboratory investigations showed Hb: 7.6 g/dL, platelet: 1.4×10^5 /dL, TLC: $12400/\text{mm}^3$, D-Dimer: 1240ng/mL, procalcitonin level: 2.6 ng/mL, PT/INR: 15 seconds/1.22, erythrocyte sedimentation rate (ESR): 60 mm/h and C reactive protein: 42 mg/L. The patient remained stable under this ventilation mode for the next 24 hours with a fluctuating radial pulse rate of 92–144/min and a respiratory rate of 24–33/min. Based on this clinical presentation, fat embolism and pulmonary embolism were considered possible diagnoses. There was no axillary/ subconjunctival petechiae, no fat globules in the urine, and a venous Doppler ultrasound of the bilateral calf was negative for deep vein thrombosis. On a postoperative day 5, total bilirubin was 3.2 mg/dL, unconjugated bilirubin: 2.0 mg/dL, and ALT/AST: 79/84 U/L on a normal renal function test. The ESR of the patient was 54 mm/h along with raised serum lactate dehydrogenase (LDH) levels: 340 IU/L, while a peripheral smear revealed no toxic granules. No pulmonary thrombus was identified on CT, while bilateral diffuse ground glass opacity in the lungs, patchy consolidations and nodular septal thickening suggestive of acute respiratory distress syndrome (ARDS) were identified (Figure 1b). The PCR COVID test was negative. Two units of packed red cells were transfused and a computer tomography (CT) of the chest along with an angiography were performed (Figure 2a). The patient deteriorated over the next 24 hours (postoperative day 6) with an Hb of 7.8 g/dL (after 2 units of packed cell transfusion), platelet: 1.8×10^5 /dL, TLC: $16600/\text{mm}^3$, total bilirubin: 7.8 mg/dL, unconjugated bilirubin: 4.8mg/dL, ALT/AST: 118/142 U/L, LDH: 480 IU/L and PT/INR: 16 sec/1.42. A routine urine examination revealed proteinuria and hematuria. Serial bronchoscopy and lavage (BAL) were performed and revealed bloody aliquots. The bronchoalveolar lavage (BAL) culture was sterile for bacteria and fungus and depicted blood clots, but few lipid-laden macrophages. After ruling out the possibility of embolism, vasculitis was considered as the causative factor. A careful elucidation of the patient's past surgical history revealed similar episodes of postoperative hemoptysis 8 years earlier (fore-

arm plating surgery) that resolved without any specific intervention. The patient had a palpable purpuric lesion measuring 7*12 cm on his back that had been there for 20 years.

Treatment was initiated with an injection of methylprednisolone (80mg twice daily for 3 days and then tapering over the next 10 days to a 10mg daily dose) and an injection of tranexamic acid 500mg three times a day, and BIPAP ventilation was continued. The frequency of hemoptysis attacks and cough decreased, and the infiltrations also improved over the next 10 days, as shown on chest radiography (Figure 2b). The patient was hemodynamically stable with a respiratory rate of 18–20/min with SpO₂- 92-96% on room air. Hb had increased to 10.4 g/dL, TLC: 8900/mm³, platelet: 1.6 lac/dL, total bilirubin: 2.1mg/dL and PT/INR: 14 seconds/1.1. The Anti-GBM antibodies were negative but cANCA (PR3) positive with CRP: 20mg/L and ESR: 36 mm/h (on postoperative day 10). provisional diagnosis of granulomatosis with polyangiitis was made and the patient was managed accordingly. The patient was gradually weaned off BIPAP support and was stable in room air. On postoperative day 16 the sutures were removed with no wound complications and the patient was discharged with a prescription of corticosteroid 10 mg daily, methotrexate 15mg once weekly, and nebulization in consultation with a rheumatologist.

At 2 2-month follow-up, the patient had no complaint of cough, dyspnea, hemoptysis or hematuria, and was mobile with the help of a stick.

DISCUSSION

DAH is a life-threatening condition triggered by various disorders in which the primary pathology involves disturbances in pulmonary microcirculation and alveolar capillaries, leading to an accumulation of red blood cells in alveoli (2-5). There is a lack of consensus on the diagnostic criteria of DAH, although it is characterized by hemoptysis, dyspnea, hypoxemia, sudden falling hematocrit and bronchoalveolar lavage findings, as well as chest radiograph and CT correlation (2,4). There is a high incidence of mortality and morbidity associated with DAH, which is further increased by delayed diagnosis. There are various etiologies of DAH, including fat embolism, pulmonary embolism, vasculitis-like Goodpasture syndrome, Wegner granulomatosis, systemic lupus, infection, hemosiderosis, drug-induced, etc. (4-7). DAH can mimic other morbid conditions, such as pulmonary embolism, fat embolism, etc. There have been a few studies to date reporting DAH to occur post-operatively in orthopedic surgeries, most of which report fat embolism associated

with DAH (3,8). Orthopedic surgeries, especially intramedullary nailing, have been associated with a high chance of fat embolism.

The presentation of DAH is similar to other life-threatening disorders, and so identifying the etiology is vital for optimum management. The clinical signs of sudden decreased SpO₂ and blood pressure are common in fat and pulmonary embolisms, and similarly, ARDS-like changes can be noted on radiographs (9). The suggestive changes, although not specific to pulmonary embolism, were not evident in our case, however, a pulmonary embolism was ruled out based on the lack of evidence of a pulmonary thromboembolism on chest CT angiography. Diagnoses of fat embolism can be supported by various criteria (10–12), but the presented case did not meet any of these. The event occurred on postoperative day 4, which is outside the window determined for fat embolism (2-3 days), although fat embolisms have been reported to occur as late as 2 weeks postoperatively (8).

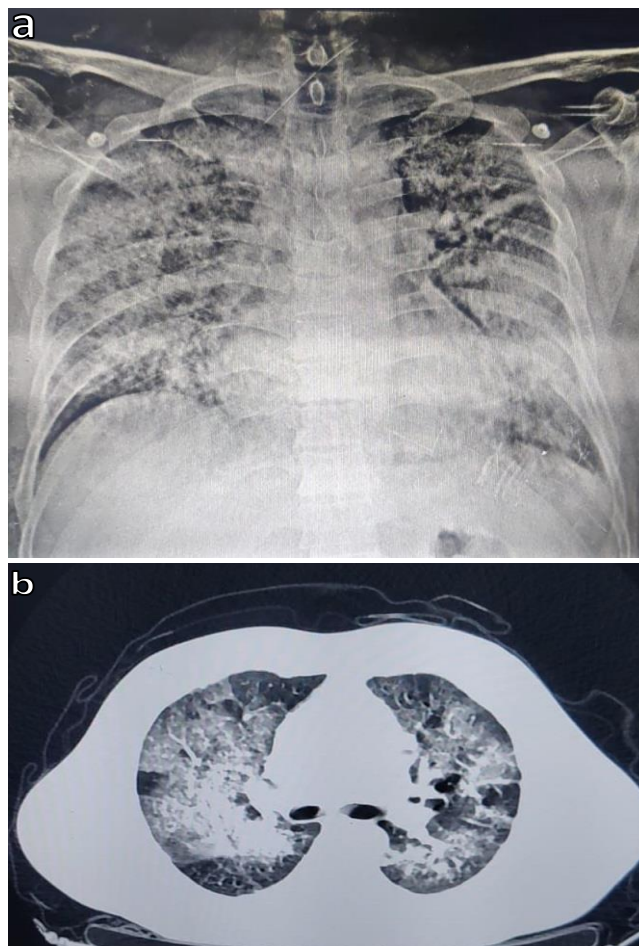


Figure 1a and b: Chest radiograph depicting alveolar infiltrates and ground glass opacity in both lungs (a), CT chest depicting diffuse ground glass opacity of bilateral lungs, patchy consolidation, and nodular septal thickening (b)

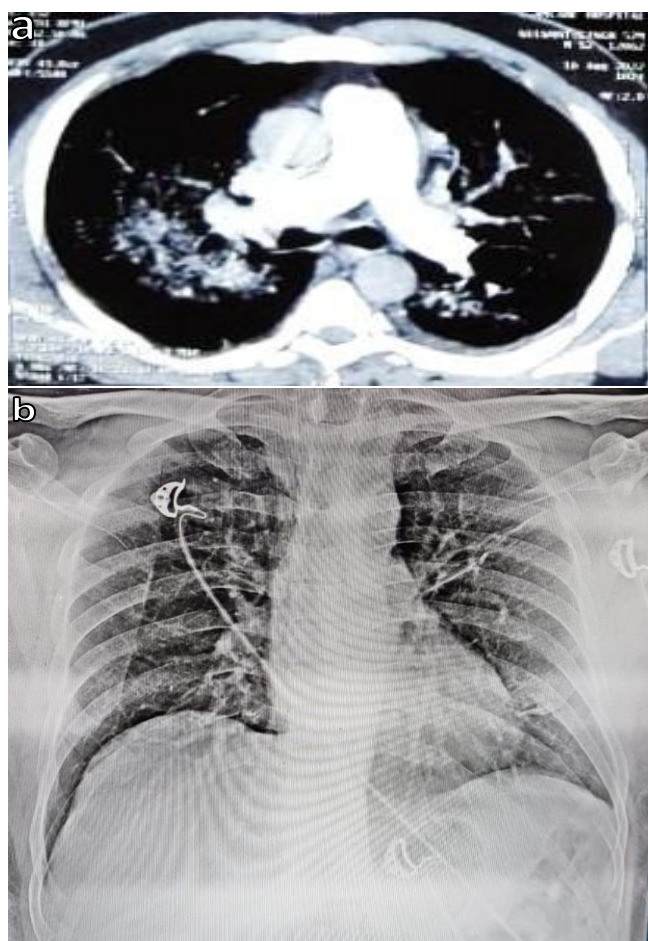

Figure 2a and b: CT angiogram of the chest (a), Chest radiograph depicting resolution of infiltrates and consolidation (b)

Vasculitis-like granulomatosis with polyangiitis, Goodpasture syndrome, etc. inherently cause inflammation of the pulmonary vasculature in the patient, and is accentuated due to trigger-like surgery, leading to altered capillary permeability and an intra-alveolar accumulation of blood. Such vasculitis disorders can exist in patients for years without their knowledge before symptoms arise due to an inciting factor. In our case, surgery was the triggering factor leading to DAH. A similar event in a past postoperative period in the patient led us to look for immune causes of DAH. Our investigations in this direction revealed anti-GBM antibodies to be negative but cANCA (PR3) to be positive, raising the suspicion of granulomatosis with polyangiitis. To the best of our knowledge, this is the first case report of a case of DAH in granulomatosis with polyangiitis in a postoperative patient. Flexible bronchoscopy can help in the diagnosis and management of DAH. Serial BAL lavage specimens in fat embolism-associated DAH can reveal increased hemorrhage, hemosiderin-laden macrophages and lipid-laden macrophages (4-6), although BAL should not be considered diagnostic for any specific disorder leading to DAH. BAL also helps to remove intra-alveolar red blood cells and improve ventilation. Our patient was not on any

anticoagulant medication, and had no sign of infection, skin rash, or any cardiac or renal disorders.

The management of such conditions should be initiated as soon as possible to ensure an optimum outcome, as the mortality rate of DAH has been reported in the range of 20–100%. Identifying etiology can support directed management and better clinical outcomes. Although management approaches are generally supportive of DAH, there are a few critical points that should be noted. The treatment of pulmonary embolisms involves the use of an anti-coagulant like heparin, which can accentuate DAH due to vasculitis (13,14), and so the use of heparin or anti-coagulant medications can be detrimental and even life-threatening in cases of DAH. It is thus important to rule out vasculitis before proceeding with management in cases of DAH. Early diagnosis and prompt treatment are the keys to better clinical outcomes. Oxygen supplementation and steroids are the mainstays of treatment, although high doses of steroids may be required in vasculitis patients. The patient responds well if treatment is initiated early following diagnosis.

CONCLUSION

DAH is a much feared but rare complication seen in orthopedic surgery. The surgeon and intensivist should be aware of the etiologies and management of the condition, as early diagnosis and treatment are the keys to a better outcome. Cases in which DAH results from vasculitis are rare, but should be investigated and managed appropriately. Patients should be investigated for vasculitis if there is any suspicion of the condition to prevent the development of life-threatening complications. The careful elucidation of subtle clues is necessary if the disorder is to be identified in asymptomatic patients.

CONFLICTS OF INTEREST

None declared.

AUTHOR CONTRIBUTIONS

Concept - B.H., S.A., L.G.; Planning and Design - B.H., S.A., L.G.; Supervision - B.H., S.A., L.G.; Funding -; Materials -; Data Collection and/or Processing - B.H., S.A.; Analysis and/or Interpretation -; Literature Review -; Writing -; Critical Review - L.G.

REFERENCES

1. Johnson MJ, Lucas GL. Fat embolism syndrome. *Orthopedics* 1996; 19:41-9. [\[CrossRef\]](#)
2. Collard HR, Schwarz MI. Diffuse alveolar hemorrhage. *Clin Chest Med* 2004; 25:583-92. [\[CrossRef\]](#)

3. Allan PF, Amjadi DK, Haynes RL. Diffuse alveolar hemorrhage: a rare manifestation of trauma. *Mil Med* 2011; 176:1071-6. [\[CrossRef\]](#)
4. Newsome BR, Morales JE. Diffuse alveolar hemorrhage. *South Med J* 2011; 104:269-74. [\[CrossRef\]](#)
5. Lara AR, Schwarz MI. Diffuse alveolar hemorrhage. *Chest* 2010; 137:1164-71. [\[CrossRef\]](#)
6. Green RJ, Ruoss SJ, Kraft SA, Duncan SR, Berry GJ, Raffen TA. Pulmonary capillaritis and alveolar hemorrhage. Update on diagnosis and management. *Chest* 1996; 110:1305-16. [\[CrossRef\]](#)
7. Park MS. Diffuse alveolar hemorrhage. *Tuberc Respir Dis (Seoul)* 2013; 74:151-62. [\[CrossRef\]](#)
8. Dash SK, Bansal A, Wankhade BS, Sharma R. Alveolar hemorrhage in a case of fat embolism syndrome: A case report with short systemic review. *Lung India* 2013; 30:151-4. [\[CrossRef\]](#)
9. Bach AG, Restrepo CS, Abbas J, Villanueva A, Lorenzo Dus MJ, Schopf R, et al. Imaging of nonthrombotic pulmonary embolism: biological materials, nonbiological materials, and foreign bodies. *Eur J Radiol* 2013; 82:e120-41. [\[CrossRef\]](#)
10. Gurd AR, Wilson RI. The fat embolism syndrome. *J Bone Joint Surg Br* 1974; 56:408-16. [\[CrossRef\]](#)
11. Lindeque BG, Schoeman HS, Dommissie GF, Boeyens MC, Vlok AL. Fat embolism and the fat embolism syndrome. A double-blind therapeutic study. *J Bone Joint Surg Br* 1987; 69:128-31. [\[CrossRef\]](#)
12. Schonfeld SA, Ploysongsang Y, DiLisio R, Crissman JD, Miller E, Hammerschmidt DE, et al. Fat embolism prophylaxis with corticosteroids. A prospective study in high-risk patients. *Ann Intern Med* 1983; 99:438-43. [\[CrossRef\]](#)
13. Santalo M, Domingo P, Fontcuberta J, Franco M, Nolla J. Diffuse pulmonary hemorrhage associated with anticoagulant therapy. *Eur J Respir Dis* 1986; 69:114-9.
14. Hayashi S, Maruoka S, Nakagawa Y, Takahashi N, Hashimoto S. Diffuse alveolar hemorrhage associated with low molecular weight heparin. *Respirol Case Rep* 2013; 1:2-4. [\[CrossRef\]](#)